

## Efficacy of Peri-Incisional Multimodal Drug Injection Following Operative Management of Femur Fractures

Daniel Koehler, MD<sup>1</sup>; Larry Marsh, MD<sup>2</sup>; Matthew Karam, MD<sup>3</sup>; Catherine Fruehling, BA<sup>1</sup>; Michael Willey, MD<sup>2</sup>

<sup>1</sup>University of Iowa Hospitals and Clinics, Iowa City, Iowa, USA;

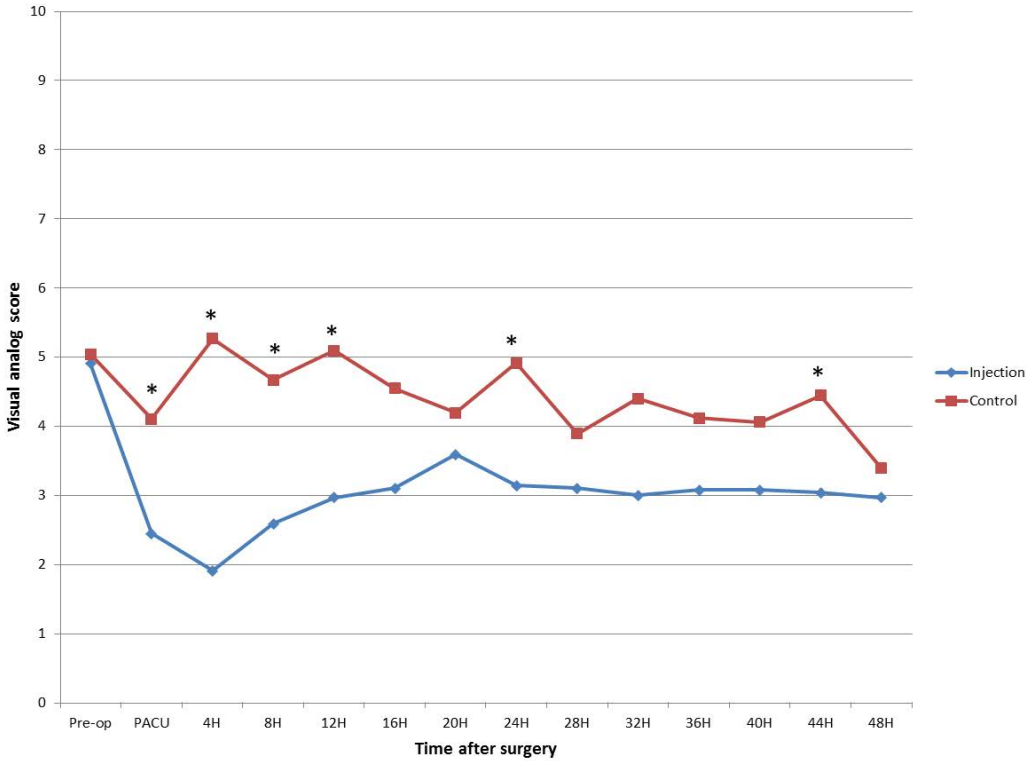
<sup>2</sup>University of Iowa, Iowa City, Iowa, USA;

<sup>3</sup>University of Iowa Hospitals and Clinics, Dept of Orthopaedics, Iowa City, Iowa, USA

**Background/Purpose:** Parenteral narcotics are currently a mainstay for perioperative pain control following operative management of femur fractures despite notable side effects including nausea, emesis, pruritus, constipation, urinary retention, confusion, sedation, and respiratory depression. Optimally, an analgesic regimen should limit adverse effects, block pain at its site of origin, and maintain muscle control to allow for early postoperative mobilization. Recently, periarticular injection with employment of local anesthetics has been introduced into the elective lower extremity arthroplasty literature as a means of achieving these goals with promising results. If this simple intervention were found to be effective it could easily be widely adopted to improve pain management for patients with femur fractures. This study was designed to evaluate the efficacy and safety of a peri-incisional multimodal drug injection for postoperative pain control following operative management of femur fractures.

**Methods:** 102 patients aged  $\geq 18$  years (range, 29-97) undergoing surgery (open reduction and internal fixation, intramedullary device, or arthroplasty) for an acute femur fracture were prospectively randomized to receive an intraoperative, peri-incisional injection (400 mg ropivacaine, 0.6 mg epinephrine, 5 mg morphine) into the superficial and deep tissues or to receive no injection. Spinal anesthesia, regional anesthesia, and protocolized preoperative analgesic regimens were not permitted in the study protocol. Exclusion criteria included: revision procedures, regular narcotic use, psychiatric illness, dementia, neuromuscular deficit, allergies to cocktail ingredients, and clinical status that precluded verbal pain assessment. The primary outcome measure was visual analog pain scores assessed at 4-hour intervals for the first 2 postoperative days. Total narcotic consumption in morphine equivalents was recorded over 8-hour intervals as well as medication-related side effects. Patients and nurses performing the postoperative assessments were blinded to the treatment. Surgeons were not blinded and were not involved in recording outcome measures. Intention-to-treat statistical analysis was employed.

**Results:** The peri-incisional injection ( $n = 45$ ) and control ( $n = 50$ ) groups as randomized were similar across all demographic parameters including the distribution of surgical interventions. The injection cohort demonstrated significantly lower visual analog pain scores compared to the control cohort in the recovery room and at the 4, 8, and 12-hour postoperative time points (Fig. 1). Additionally, narcotic consumption was significantly lower in the injection group than the control group ( $6.5 \pm 7.5$  mg vs  $10.8 \pm 9.3$  mg) over the first 8 hours following surgery. No cardiac or central nervous system toxicity was observed secondary to infiltration of the local anesthetic.



**Conclusion:** Peri-incisional injection with a multimodal analgesic cocktail offered improved pain control and decreased narcotic utilization over the first postoperative day, with no apparent risks, for patients undergoing operative intervention for acute femur fractures. Decreased narcotic consumption may limit medication-related adverse effects in a predominantly elderly population.

The FDA has stated that it is the responsibility of the physician to determine the FDA clearance status of each drug or medical device he or she wishes to use in clinical practice.