

Better Clinical and Radiographic Outcomes with Suture Endobutton Compared to Syndesmotic Screw in Treatment of Syndesmotic Injuries:

A Randomized Controlled Trial

Mette Andersen, MD¹; Frede Frihagen, MD, PhD²; Johan Hellund, MD, PhD³;
Jan Erik Madsen, MD, PhD²; Wender Figved, MD, PhD¹

¹Department of Orthopaedic Surgery, Baerum Hospital, Vestre Viken HF, Drammen, NORWAY

²Department of Orthopaedic Surgery, Division of Surgery and Clinical Neuroscience, Oslo University Hospital, Oslo, NORWAY

³Department of Radiology and Nuclear Medicine, Oslo University Hospital, Oslo, NORWAY

Purpose: Anatomic reduction of the tibiofibular joint is associated with better functional outcome and less posttraumatic arthritis. There is a great variability in methods of fixation, perhaps as a result of the lack of evidence supporting one method over another. The purpose of this study was to compare clinical results after stabilization of the acute injured syndesmosis with suture endobutton (SE) or one quadricortical screw (SS).

Methods: 97 patients between 18 and 70 years of age with syndesmotic injuries were randomized into two groups (SE =48, SS = 49). 95 patients had concomitant OTA / AO ankle fracture type 44-C and 2 patients had an isolated syndesmotic injury. The two groups were similar regarding gender, age, and body mass index (BMI). The syndesmotic screw was removed 10-12 weeks after surgery as a routine. Rehabilitation was standardized for both groups; partial weight bearing was allowed after 2 weeks and full weight bearing was allowed after 6 weeks. Dorsiflexion ad modum Lindsjo and functional outcome scores were obtained after 6 weeks, 6 months, and 1 year. Main outcome measure was the modified American Orthopaedic Foot & Ankle Society ankle hind-foot score (AOFAS). Conventional radiographic examination of the injured ankle was obtained after surgery, 6 weeks, and 6 months. CT scans of both ankles were obtained within 2 weeks after surgery and after 1 year. The examinations were standardized with the ankles in neutral position and legs in 20° internal rotation. The syndesmosis was assessed on axial scans 1 cm proximal to the tibial plafond. The tibiofibular distance (TFD) was measured at three standardized points (Fig. 1), and the difference between the width of the oper-

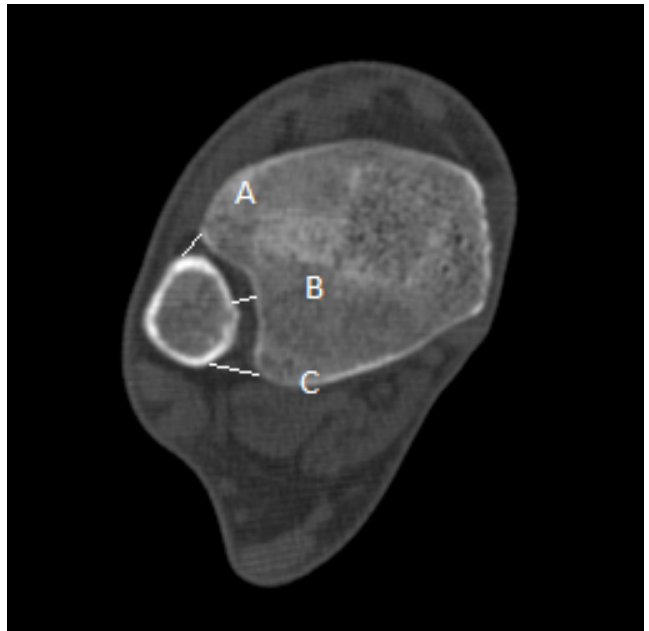


Fig 1: Axial CT scan with measurements (A=anterior, B=central, C=posterior)

The FDA has stated that it is the responsibility of the physician to determine the FDA clearance status of each drug or medical device he or she wishes to use in clinical practice.

ated and nonoperated ankle was calculated. Rate of complications and reoperations were recorded. 85 patients (88%) completed 1-year follow-up (SE = 46, SS = 39).

Results: Patients treated with SE presented with better AOFAS after 6 weeks (63 vs 58, $P = 0.13$), 6 months (88 vs 82, $P = 0.02$), and 1 year (93 vs 84, $P = 0.001$). Also Olerud Molander Score was better in the SE group after 6 weeks (35 vs 32, $P = 0.41$), 6 months (81 vs 68, $P = 0.001$), and 1 year (90 vs 80, $P = 0.02$). The difference in maximal dorsiflexion between injured and noninjured side was smaller in the SE group than the SS group after 6 weeks (-17.1 vs -20.9° , $P = 0.08$), 6 months (-7.6 vs -10.9° , $P = 0.04$), and 1 year (-4.7 vs -7.6° , $P = 0.05$). Number of patients with TFD between operated and nonoperated ankle of 2 mm or more were higher in the SS group after 1 year: anterior, 23 (58%) vs 12 (28%) ($P = 0.008$); central, 18 (45%) vs 10 (23%) ($P = 0.04$); posterior, 17 (43%) vs 10 (23%) ($P = 0.1$). Seven patients (15%) in the SS group were diagnosed with recurrent syndesmotic diastasis during the treatment period compared to none in the SE group ($P = 0.005$). Three patients (6%) in the SE group required suture endobutton removal within the first year after surgery due to discomfort associated with the lateral knot.

Conclusion: Suture endobutton is a better alternative than one quadricortical screw in the treatment of syndesmotic injuries in patients below 70 years of age, because it provides better anatomical restoration and superior clinical results.