

Femoral Anatomy Changes with Age Predisposing to Distal Anterior Malpositioning of Intramedullary Implants

Damien M. Tucker, MBChB, MRCS¹; T. Surup, Dip Eng²; Andreas Petersik, PhD²;

M. Acharya, MD¹; T. Chesser, MD¹; M. Kelly, MD¹;

¹North Bristol NHS Trust, Bristol, United Kingdom

²Stryker R&D Virtual Engineering, Kiel, Germany

Purpose: Anterior positioning of a cephalomedullary nail (CMN) in the distal femur occurs in up to 88% of cases. Conventionally, this is considered to occur because of a mismatch between the radius of curvature (ROC) of the femur and that of available implants. The hypothesis for this study was that the relative thicknesses of the cortices of the femur, particularly the posterior cortex, are important in determining the final position of an intramedullary implant and that the posterior cortical thickness corresponds to the linea aspera anatomically. The aim was to determine if these measurements changed with age.

Methods: This study used the data from CT scans undertaken as part of routine clinical practice in 919 patients with intact left femora (median age 66 years, range 20-93 years; 484 male and 435 female). The linea aspera was defined manually on the template bone by consensus between two orthopaedic surgeons and two anatomists. The length of the femur was measured from the tip of the greater trochanter proximally to the intercondylar notch distally. Transverse intervals were plotted on the femur between 25% and 60% femoral bone length (5% increments). The linea aspera was then defined at each interval on the template bone and mapped automatically to all individual femora in the database. Measurements of cortical diameters and orientation were then made as shown in Figure 1.

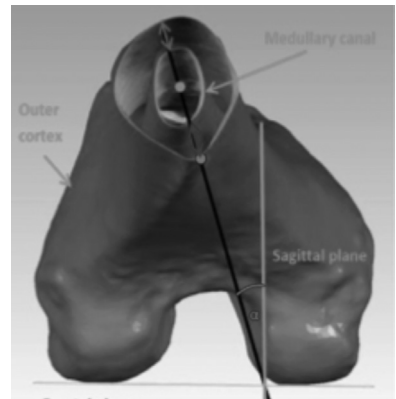


Figure 1: Definitions and measurements at an interval of femoral bone length

Results: The linea aspera was found to be internally rotated as compared to the sagittal plane referenced off the posterior femoral condyles. An age-related change in the posterior/anterior cortical thickness ratio was demonstrated. This ratio increases in all age groups from 25% to 60% bone length being maximal around 45% to 55% bone length. The ≥ 80 -year-old cohort shows a disproportional posterior/anterior ratio increase of 70.0% from 25% to 50% bone length as compared to 48.1% for the < 40 -year-old cohort (Table below), which is statistically significant (Mann-Whitney test $P < 0.05$, $\alpha = 5\%$).

- The FDA has not cleared this drug and/or medical device for the use described in this presentation (i.e., the drug or medical device is being discussed for an "off label" use). For full information, refer to page 600.

Table. Median Posterior/Anterior Cortical Thickness Ratio Changes Along Femoral Bone Length

Measurement position→ Age group↓	25% bone length	30% bone length	35% bone length	40% bone length	45% bone length	50% bone length	55% bone length	60% bone length
<40 years	1.08	1.23	1.30	1.39	1.51	1.60	1.58	1.45
≥80 years	1.00	1.08	1.19	1.33	1.49	1.70	1.73	1.61

Conclusion: This study presents a novel method of investigating femoral anatomy with directly relevance to orthopaedic procedures. This study has shown that assessment in the sagittal plane may be inaccurate because the linea aspera changes in this plane throughout the length of the femur. It also shows the loss of the centering influence of the cortices with age with a relative thinning of the anterior cortex with a concomitant thickening of the posterior cortex moving distally in the femur. This has a very direct and significant influence on the positioning of intramedullary femoral implants, explaining the preponderance of anterior malpositioning of intramedullary implants in the elderly.